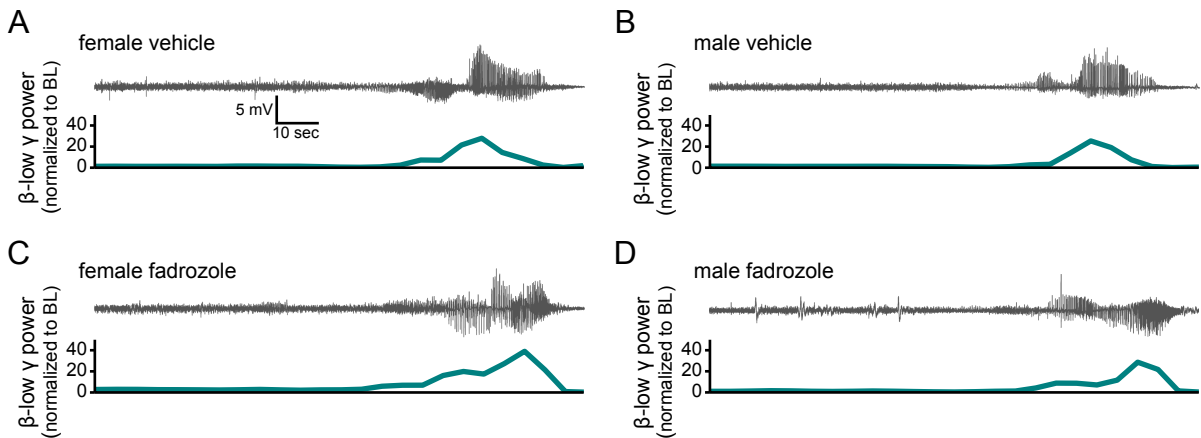


Figure 1 - figure supplement 1

Representative 1st electrographic seizures before i.v. Veh/Fad injection



No difference in characteristics of 1st seizures in gonadectomized rats

