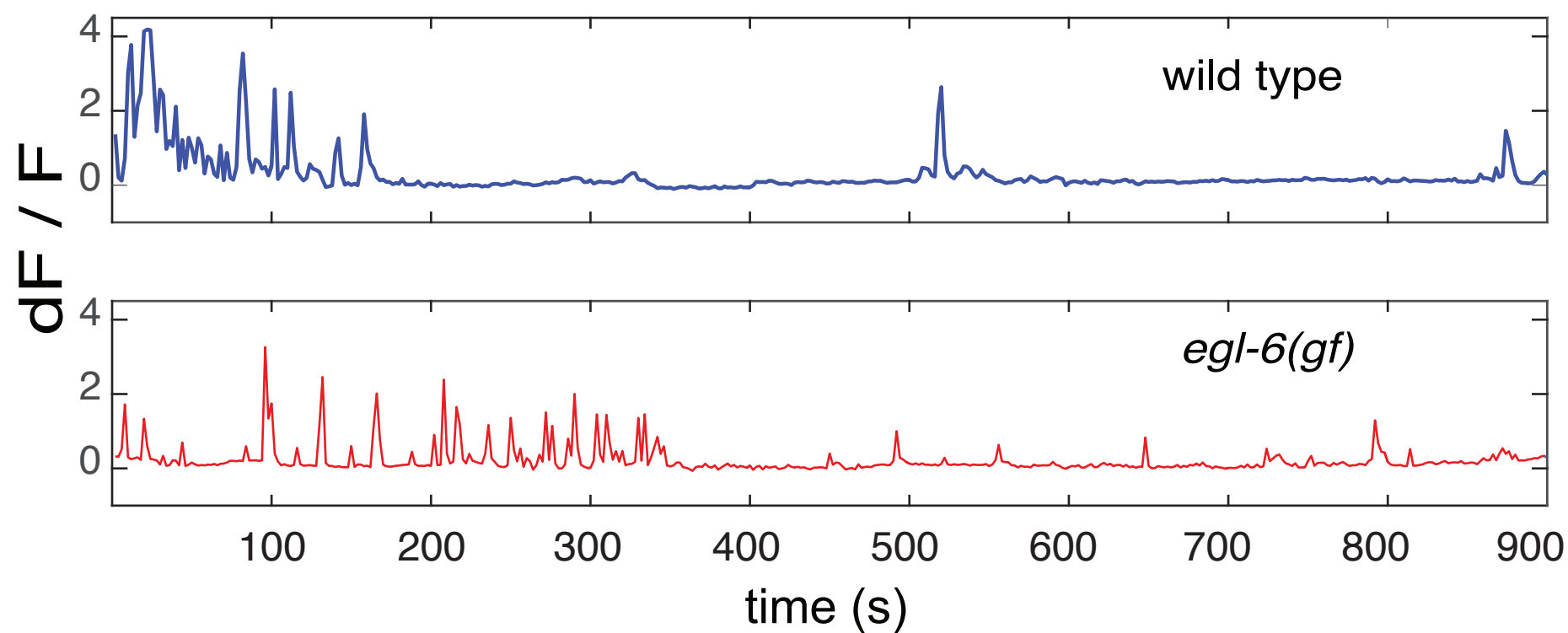


A

Calcium imaging from Vulval Muscles



B

