

A

Ventromedial Hypothalamus (VMH)

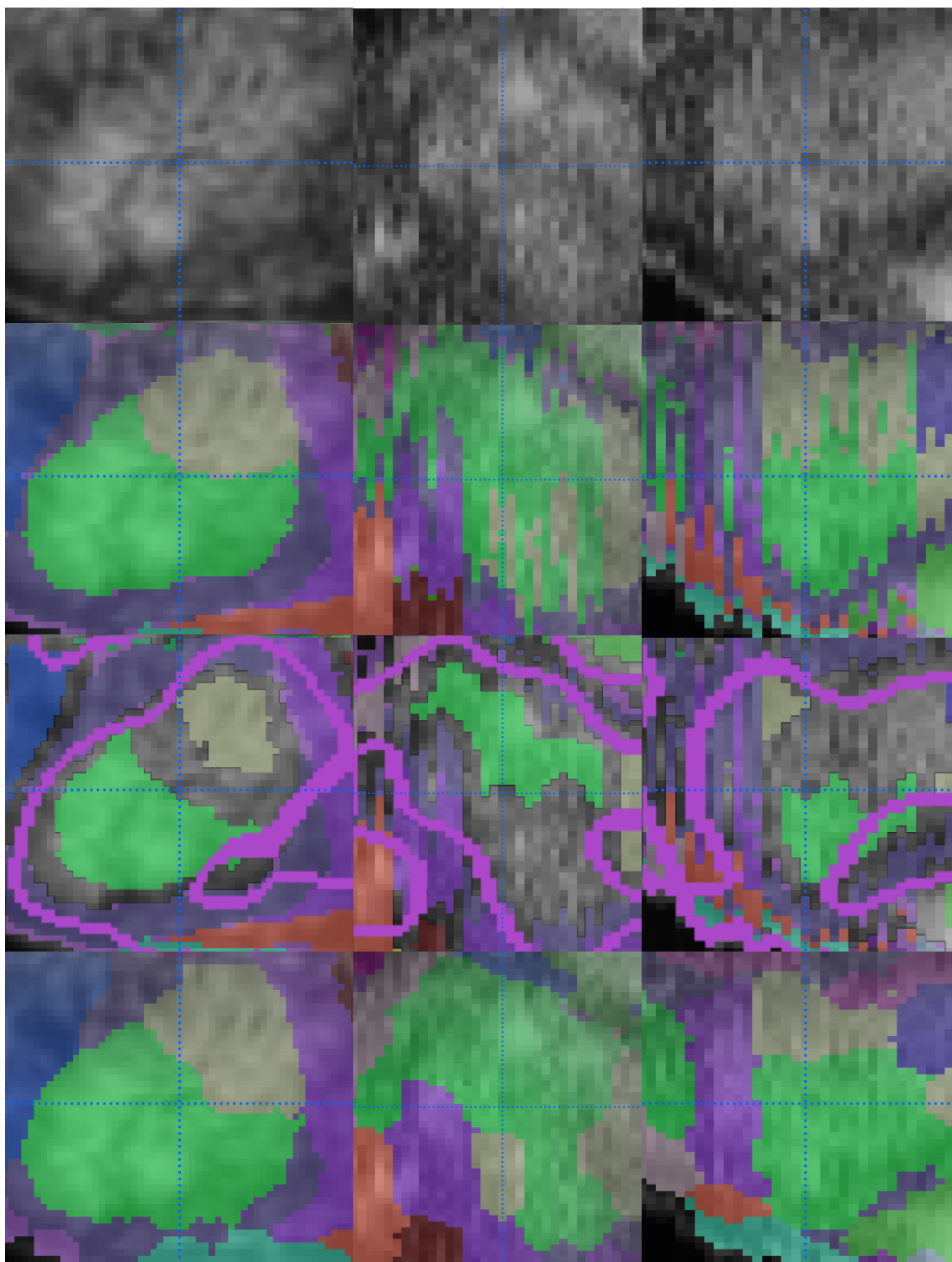
Sagittal

Axial

Coronal

Microscopy

Original Labels

Eroded Labels with
Anatomical MapSmoothed Labels
(Edge-Aware)

B

Pontine Hindbrain

Sagittal

Axial

Coronal

