

Figure 1-figure supplement 1

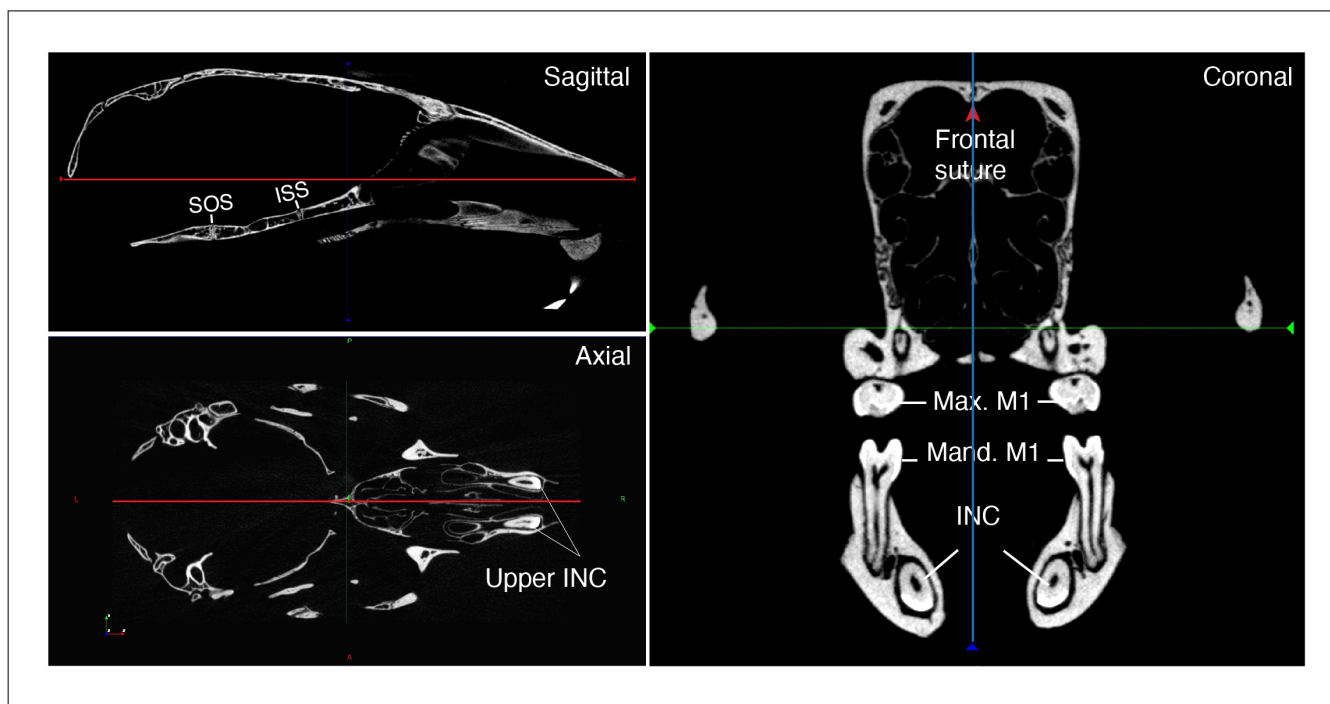


Figure 1-figure supplement 1. Orientation of skulls in sagittal, axial and coronal planes. Max: Maxillary; Mand: Mandibular; M1: first molar; INC: Incisor; ISS: Intersphenoid synchondrosis; SOS: Spheno-occipital synchondrosis.