

### Degeneration and regeneration of the cerebello-vestibular tract

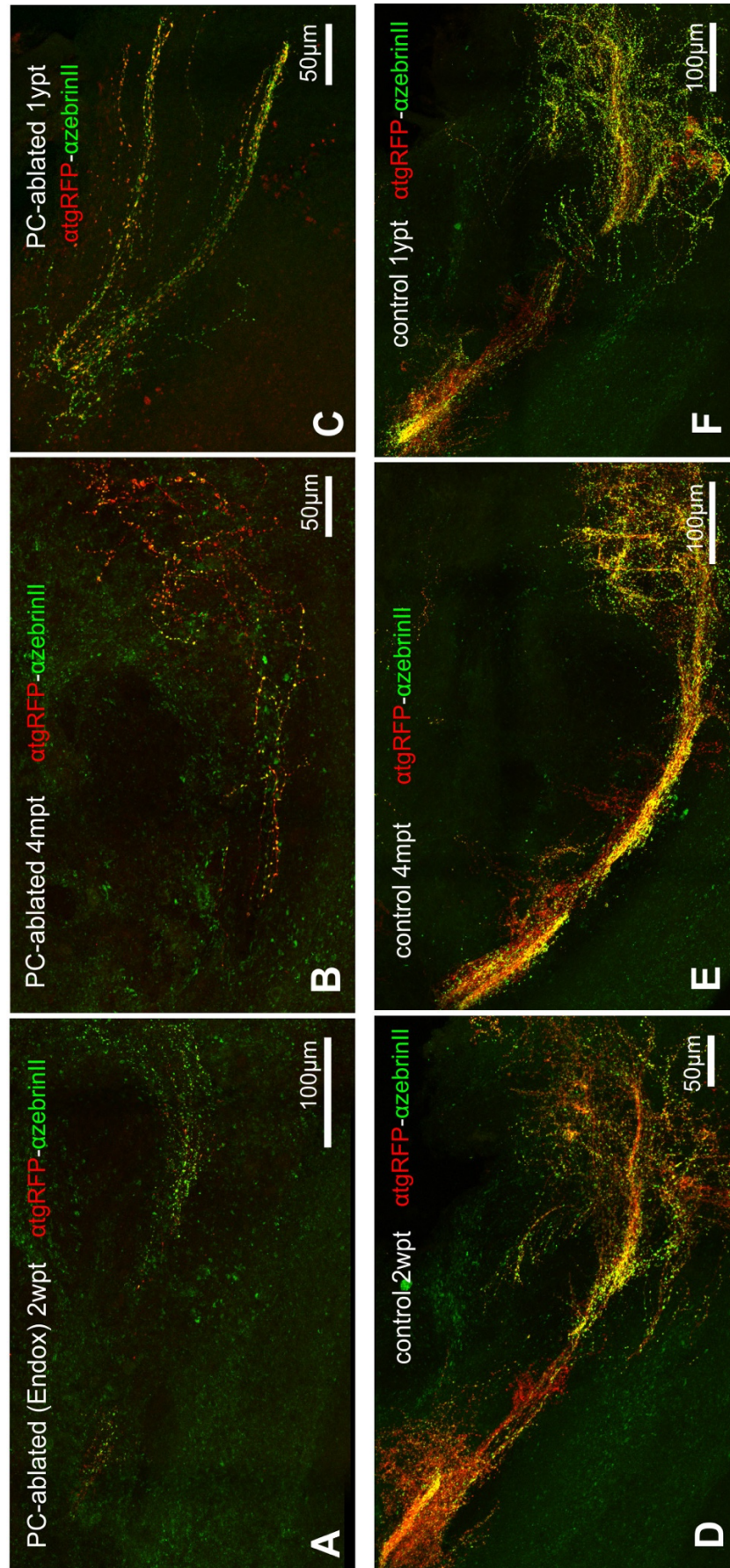


Figure 6-figure supplement 3