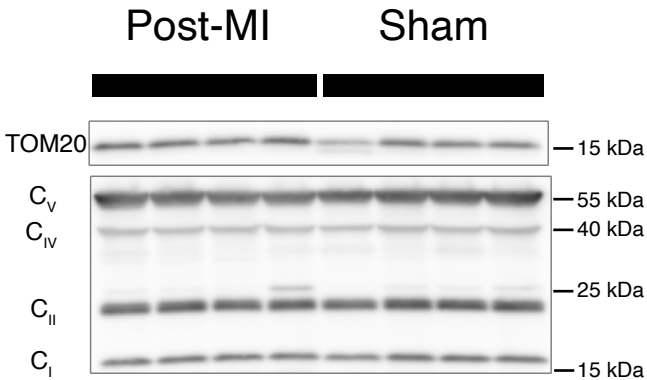
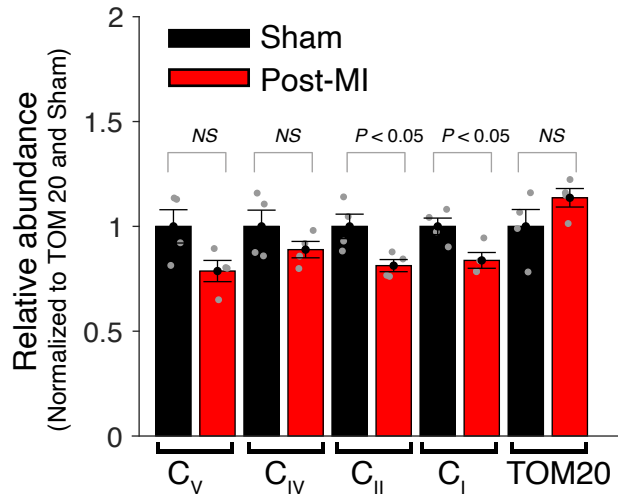


A

Posterior wall

**B**

Posterior wall

**C**

Septum

